Notes

Orthopedic examination and selected orthopedic problems in small animals

Daniel Koch Dr. med. vet ECVS
Small Animal Surgery Referrals
Rhyäcker 7
8253 Diessenhofen / Switzerland
www.dkoch.ch

Contents

1 General orthopedics

1.1 Examination of the orthopedic patient

Order of examination		Manipulations, test	Some diagnostical advices
Anamnesis	Signalment	- breed predilection	Dachshound: disk herniation; Bernese mountain dogs, German shepherd dogs, Rottweilers, Retrievers: elbow dysplasia; Dobermann pinschers: Wobbler's syndrome
		- size	Small dogs: patellar luxation to medial, Legg Perthes; large dogs: patellar luxation to lateral, elbow dysplasia, hip dysplasia, cruciate ligament rupture
		- age	young dogs: OCD, panosteitis; old dogs: arthrosis, tumors, cruciate ligament rupture
	Anamnesis	- First open questions („what is the problem"), let the owner talk, then: - closed questions: „since when…." „how happened, accident ?..." „when do you see the lameness…" "lameness increasing?..." "premedications, success…" "use of the pet…." Other questions	50 % of all lamenesses come out of the stifle joint lameness at the beginning = degenerative; at the end: inflammatory Toes on the ground, difficulties with stairs and jumping into the car with hip dysplasia and coxarthrosis
Gait	Getting up	Look at the pet after long phases of inactivity: - getting up - first 2-3 steps	Many lamenesses are very discreet, they shall not be missed; these speak for degenerative processes
	Standing	- position of the leg (rotation, position to body) - stretching of the head - bending of the back, hindlegs under body - axial deviations (varus, valgus)	Relief of the hindlimbs Relief of the frontlimbs Growth disturbances (radius curvus, trauma to physis)
	Locomotion	- First 10 – 15 meters in normal steps, then in trot - find out the affected side (without weight bearing or shorter stride, head on healthy side) - eventually make circles, go on stairs, jumps - specify the degress of the lameness (1-4)	Lameness during weight bearing: distal problem Lameness in hanging phase: proximal problem Intermittent lameness hindlimb: probably patellar luxation (PL)

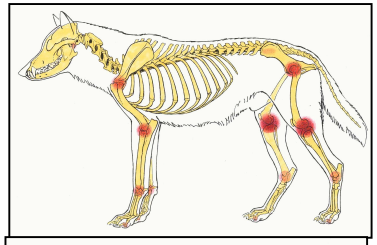

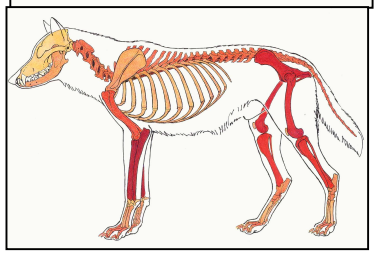

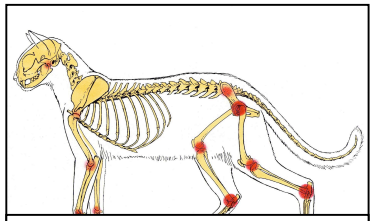

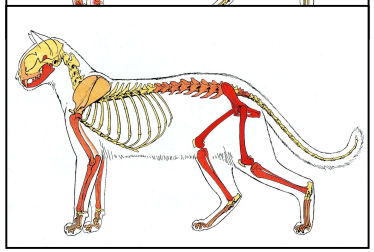

Examination in upright position

General principles:
- examination from distal to proximal
- affected extremity as the latest
- compare with contralateral limb
- repeat the tests
- painful tests at the end

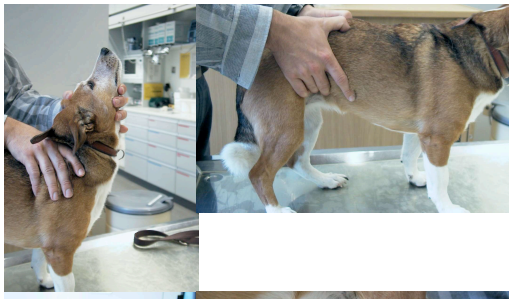

Short neuro-check	- Check proprioception - turn head into all directions - palpate the vertebral column - perform other neurological examinations if necessary	It is important to exclude an existing neurological problems, e.g. disk herniation
Hindlimb	- pull test on tarsi	Determination of affected side
	- pain mass test on toes	Fractures, tumors, sesamoid disease
	- check joint effusions and masses on tarsus	OCD, fracture
	- palpate long bones (tibia, fibula)	Panosteitis, fractures, tumors
	- palpate patella and check for painful manipulations	Patellar luxation (PL)
	- check for stifle joint effusion, masses and instabilities	CrCL rupture, PL, OCD etc
	- palpate the long bone (femur)	Panosteitis, fractures, tumors
	- assess the muscle mass on the thigh	General indication for affected side
	- extend, abduct and flex the hip joint	Hip dysplasia, Arthrosis, myopathies
	- extend and rotate inwards the hip joint	Iliopsoas strain
	- compare distance of the sciatic tuber and the great trochanter	Hip luxation
	- make hyperextensions of the lumbosacral joint	Lumbosacral problems, spondylosis, fractures
Frontlimb	- push test carpus	Determination of affected side
	- carpal joint: effusions, masses	Fractures, tumors, sesamoid disease Hyper extension trauma, M. abd. Poll. Long.
	- palpate long bones	Panosteitis, fractures, tumors
	- compare elbow joints	Elbow dysplasia, luxations, arthrosis
	- inward and outward rotation of limb with elbow joints in 90°	Elbow dysplasia, elbow luxation
	- shoulder joint: abduction of maximally 20° whilst extensions of elbow and shoulder joint	Medial luxation
	- biceps test: deep palpation of medial shoulder joint or insertion on radius	Tenovaginitis of the biceps tendon
	- check muscle mass on shoulder joint	General indication for affected side

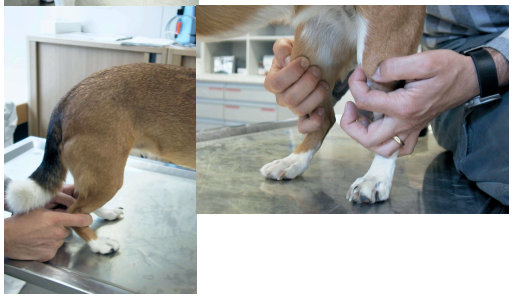

Examination in lateral recumbency	Hindlimb	Phalangeal joints:	
		- Flexion and extension of all joints	Fractures
		- Overextension of metatatarso phalangeal joints	Sesamoid disease, polyarthritis, leishmaniosis
		Metatarsus:	
		- Palpation of the bones	Fractures
		Tarsus (with stifle joint flexed):	
		- 165° extension is normal, flexion until metatarsals are parallel to femur	
		- check short collaterals in flexion	Rupture of the collateral ligaments or malleolar fracture
		- check long collateral in extension	Rupture of the collateral ligaments or malleolar fracture
		- all intertarsal joints must be stable	Trauma, fractures, luxations
		- check medial tarsus for pain in flexion	OCD of the medial talus
		Tibia / Fibula:	
		- Palpation	Panosteitis, fractures, tumors
		Stifle joint:	
		- Flexion, extension, look for pain and crepitation	Osteoarthritis, meniscal problem, Salter Harris fractures
		- drawer sign and positive tibia compression test with slightly flexed stifle joint	Cranial cruciate ligament rupture
		- deep medial palpation	Meniscal problems
		- Rotation (normally 5-6° inward and outward rotation)	Increased inward rotation with partial CrCL rupture
		- check medial and lateral collaterals	
		- patella: extension of stifle and hip and inward rotation for medial PL; flexion of stifle and hip joint and outward rotation for lateral PL	Patellar luxation
		Femur:	
		- deep palpation	Panosteitis, fractures, tumors
		Hip joint:	
		- rotation of the hip joint (crepitation, pain, extreme movements)	Osteoarthritis, Legg Perthes, fractures, luxations, tumors, hip dysplasia
		- full extension and production of pain	Coxarthrosis
		- extension and inward rotation is painful	Myositis M. ilipsoas
		- deep palpation of M. pectineus	Hip dysplasia, coxarthrosis
		- Ortolani test (adduction; subluxation, abduction)	Hip dysplasia
		- Bardens test (subluxation of femur in youg dogs)	Hip dysplasia
		- Check position of greater trochanter and tuber ischiadicum	Hip luxationm, femur head fracture, acetabulum fracture

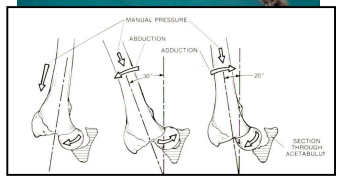

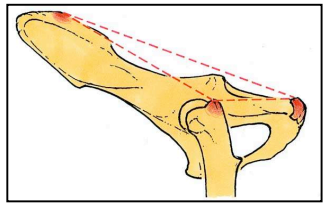

Front limb	Phalangeal joints:	
	- Flexion and extension of all joints	Fractures
	- Overextension of metatacarpo phalangeal joints	Sesamoid disease, polyarthritis, leishmaniosis
	Carpus:	
	- normal is 30° flexion, 210° extension; in flexion 5° valgus , 15° varus	Hyperextension trauma
	- drawer sign (only in cats)	Medial collateral ligament rupture
	- Finkelstein test	M. abductor pollicis longus tenovaginitis
	Radius / Ulna:	
	- Palpation	Fractures, panosteitis, tumors, HOD (distal)
	Ellbow	
	- Flexion, extension: production of crepitation and pain	Osteoarthritis, elbow dysplasia, fractures (Salter-Harris, lateral condylus), FCP, OCD, UAP (especially when lateral effusion and German Shepherd Dog)
	- Extension: Production of Pain	
	Humerus:	
	- Palpation:	Fractures, panosteitis, tumors
	Shoulder joint:	
	- Flexion, extension, abduction	Osteoarthritis, OCD, avulsion of the biceps tendon,
	- Extension: production of pain	tenovaginits of the biceps tendon, luxation
	- Deep palpation of the biceps tendon	tenovaginits of the biceps tendon
	- Check position of greater tuberculum relative to acromion	Luxation, subluxation of the shoulder joint

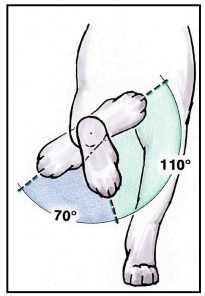

Further diagnostic tools

- Neurologic examinbation
- Radiography
- Ultrasound (Muscles, tendons)
- Computed tomography
- magnetic resonance imaging
- arthroscopy
- biopsy

References

Hazewinkel HAW, Meutstege FJ (1990): Locomotieaparaat. In: Rijnberk A., de Vries H. Anamnese en lichamelijk onderzoek bij gezelschapsdieren. Bohn, Stafleu, Van Loghum, 175 – 200.

Krämer M (1998): Der klinisch-orthopädische Untersuchungsgang der Gliedmasse, demonstriert am gesunden Hund. Ein Videofilm. Dissertation Universität Zürich.

1.2 Worksheet for the cases

Case no	Information	Remarks
Signalement		
Anamnesis		
Gait analysis		
Examination in upright position		
Examination in lateral recumbency		
Radiographs		
Diagnostic plan		
Diagnosis		
Therapeutic plan		
Others		

2 Feline trauma patients

2.1 General approach to the feline trauma patient

Most orthopedic problems in cats are due to motor vehicle incidents or falls from heights. Special consideration is given to the correct emergency treatment, which includes infusions with cristalloids or colloids, analgetics and an assessment of lung and bladder function. Up to 35 % of all pets with traffic incidents suffer from a thoracic injury (bleedings, pneumothorax, diaphragmatic hernia, rib fractures), which may need an intervention prior to orthopedic treatments.

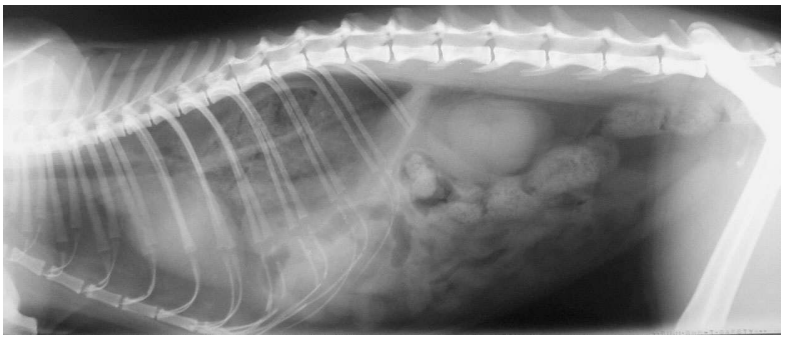

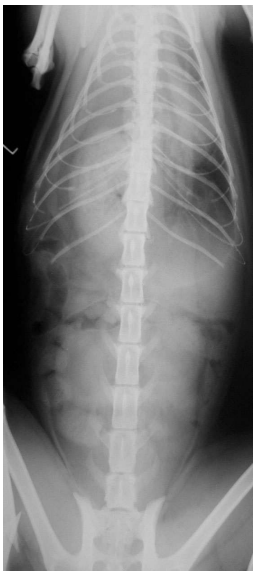

Figure 2-1: Laterolateral and dorsoventral radiographs of a cat with diaphragmatic hernia after being hit by a car.

A common approach to the injured cat is performed in a combination of diagnostics and life saving interventions. It may be necessary to fill up the cat with infusions or give oxygen, before any radiographs are taken. It is also wise to perform a thoracocentesis and thereby to evacuate air. Stress and sedation may lead to fatal complications.

Our approach is the following:

1. Perform a short clinical examination (breathing, pulse, temperature, capillary refill time, color of the mucus membranes, heart sounds, lymphnodes, check the skin and the skeleton roughly)
2. If the cat is stable, radiographs of the entire body and of regions of interest are taken in two directions
3. Infusions are given. I a severe shock, a first bolus of 100 ml / kg BW is followed by infusions rates between 3 and 6 ml / kg BW; blood and urine is collected for analysis
4. Antibiotics and analgetics are given IV

If the cat is not stable, suffering from asphyxia or severe shock, all diagnostic steps are postponed until a stable condition is achieved by providing infusions, oxygen or evacuating air. Corticosteroids have no proven effect in s shock situation.

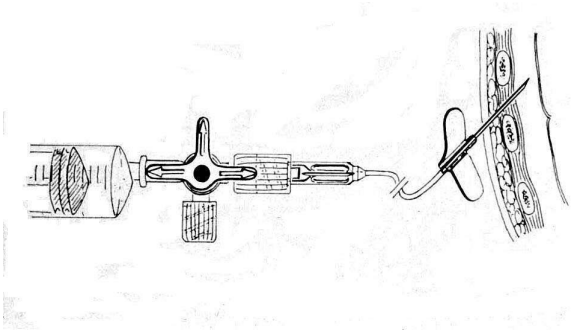

Figure 2-2: Thoracocentesis with a 20 ml syringe (left), a three-way stopcock (middle) and a butterfly needle (right).

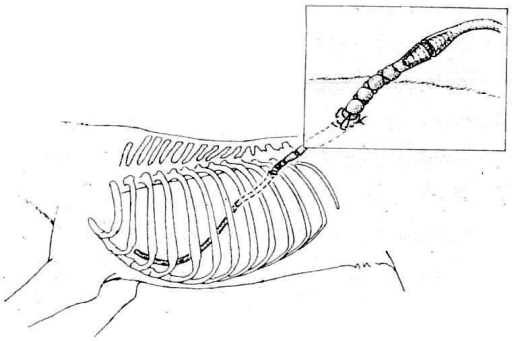

Figure 2-3: Proper positioning of the chest tube and fixation with Chinese finger traps

2.2 Degloving injuries and abrasions

Although looking badly, many abrasions have a favorable prognosis, if treated correctly. The emergency treatment is made with a wet and dry bandage (inner layer with hydrophilic cotton moistened with saline solution or Ringers solution; outer layer with hydrophobic cotton). In case of a cat in stable condition, the wound is debrided and assessed. Wet and dry bandaging is continued until a healthy granulation tissue is visible. It may be necessary to add temporary stabilisation to joints or bones by external skeletal fixators or splints.

Skin defects close by wound contraction and epithelisation during the first 30 to 40 days. After that time, a skin flap or graft may help closing remaining skin defects. Definitive joint stabilization by either ligament reconstruction, prosthesis or arthrodesis is normally made within the first 10 days after the injury.

Failures are mostly due to vascular compromise, loss of foot pads or infection. A decision can be taken within the first 5 days. High amputation is a good alternative and salvage procedure.

Figure 2-4: Material needed for a wet and dry bandage (sponges, hydrophilic and hydrophobic cotton, elastic bandages, jelly, gloves)

Figure 2-5: The hydrophilic cotton wrap is moistened with Ringers' solution before continuing with hydrophobic cotton and elastic bandage.

2.3 Skull fractures

The most common fracture is a mandibular bone separation in the symphysis. A simple cerclage wire, which is positioned behind the canine teeth and twisted ventrally, fixes the fracture adequately. Simple unilateral mandibula fractures do not require fixation, whereas bilateral fixations need at least a unilateral osteosynthesis with cerclage loops or a small maxillofacial plate.

The palate may split in the middle causing a cleft. In case of dental malocclusion or clefts exceeding 3 mm width, a tension band fixation is recommended.

Some comminuted fractures may require interarcade wiring or temporary bonding of the canine teeth. Do not forget to plan and execute an esophageal feeding tube, as many of these cats may stay anorectic for some days.

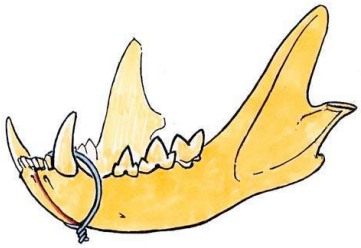

Figure 2-6: Cerclage wire to fix mandibular separation

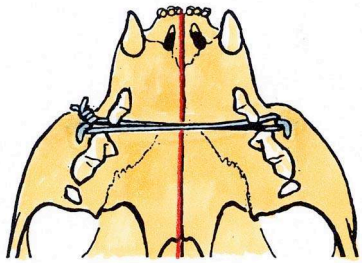

Figure 2-7: Tension band wiring for palatinal fractures

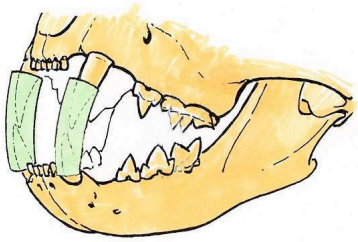

Figure 2-8: Intercaninus bonding technique as a method to stabilize the jaws in comminuted fractures

2.4 Front limb fractures and instabilities

A typical fracture pattern is the distal humerus fracture with and without joint involvement. After reconstruction of the condylar region with a lag screw, the shaft is rebuilt with medially or laterally applied plates, external fixators or plates and rods.

Figure 2-9: Humerus fracture fixation with external fixator in tie-in mode

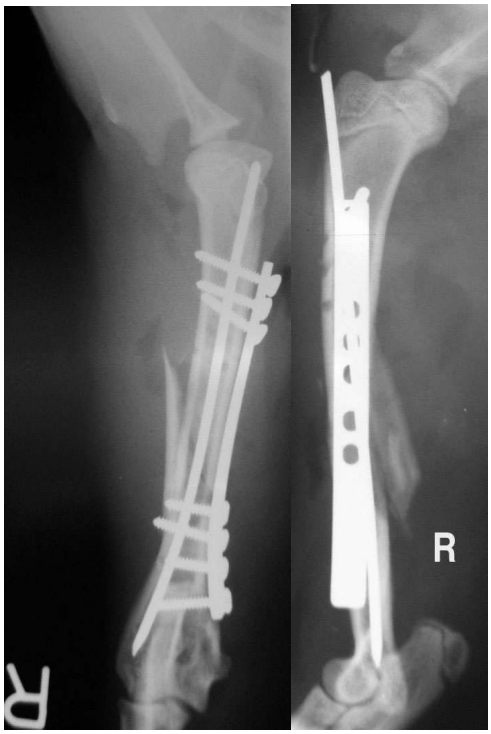

Figure 2-10: Biological humerus fracture fixation with plate on the medial aspect and 2.0 rod

Radius and ulna fracture very often must be fixed with plates on the dorsal side of the radius. Distal radius fractures require T plates or fixed angle devices (such as LCP or ALPS).

Carpal instabilities are rarely seen. As cats have increased mobility in the carpals, the medial collateral ligament is built oblique, which has to be considered during reconstruction. If ever possible, a pancarpal arthrodesis should be avoided in cats.

Figure 2-11: T-plate on a distal radius. The distal fragments are often rather small.

Figure 2-12: Cross pins as a treatment of a Salter Harris fracture in a 8 months old cat

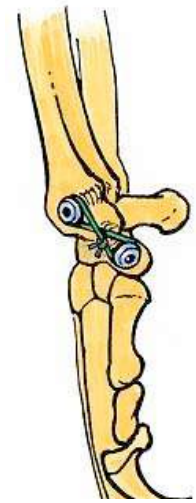

Figure 2-13: The medial collateral ligament in the feline carpus is oblique and must be reconstructed accordingly.

2.5 Hindlimb fractures and instabilities

Pelvic fractures are common. They need surgical intervention, if the acetabulum is involved or the ilial bones are broken on both sides. Plating is a straightforward method. Femoral head and neck resection is not only a salvage procedure, but also ends up in such good results, that acetabular fracture reconstruction in cats has become in infrequent procedure. Iliosacral separation however should be treated by reposition and screw fixation, if it is bilateral, or sciatic damage is expected.

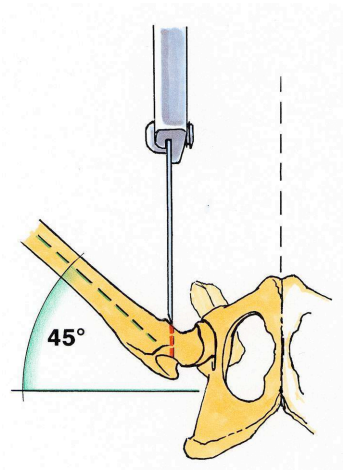

Figure 2-14: A useful approach to the hip joint is from medial. It can be used for femoral head and neck resection and for the fixation of some femur head fractures.

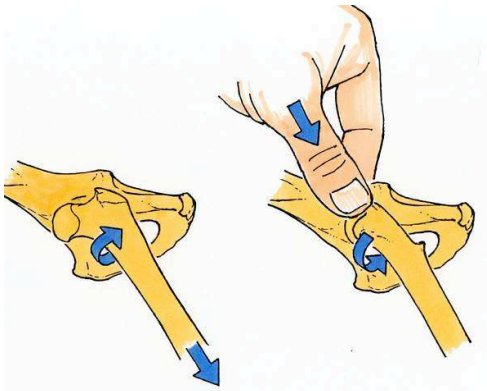

Figure 2-15: Method for the reduction of luxated hip. After successful reposition, the hip joint is held in a Slocum sling for 10 days to allow scarring around the joint capsule.

Figure 2-16: Bilateral sacroilial separation fixed with 2.7 lag screws. The ischial and pubis fracture undergoes indirect bone healing

Femur fractures in adult cats are fixed with many methods. Plating is the preferred therapy. Young cats may suffer from a Salter Harris type 1 or 2 fracture from the distal femur, which is treated with cross pins.

Cranial cruciate ligament ruptures can be treated conservatively in lean cats. If the lameness persists, an extracapsular repair is recommended (e.g de Angelis technique with heavy braided suture material).

Tibia fractures are common and may be fixed with plates, external fixators or casts upon the surgeon’s preference. Malleolar fractures are seen quite often. Tension band wiring reapposes the small fragments to the tibia and the fibula. Thereby, the tarsal luxation is reduced. Intertarsal separation may be fixed with small plates.

Metacarpal and metatarsal fracture only need fixation, if all bones are broken or if the fracture line enters a joint. Intermedullary pins are sufficient in multiple transverse fractures.

Amputation of a digit with a piece of a metacarpal or metarsal bone is a good alternative, if complications are to be expected or have occurred. All other cases are fixed with external coaptation

Open fractures of degree 2 or 3 should be fixed with external fixators to allow the surgeon to treat the open. Furthermore, avoidance of implants in the injured region does not compromise any ingrowth of new vessels and reduces the risk of bacterial adherence.

Figure 2-17: Tubular external fixator on a distal tibia with fissure lines

Figure 2-18: Malleolar fracture treated with tension band wiring and talus reconstruction with lag screws

3 Selected orthopedic problems in senior dogs

3.1 Introduction

Most of the orthopedic problems encountered in senior dogs are due to osteoarthritis. The hindlimb is most commonly affected. Coxarthrosis after juvenile hip dysplasia and cranial cruciate ligament rupture are challenging diseases. Their treatment varies considerably from conservative treatment (weight loss, NSAID, chondroproctiva, restriction of locomotion, physiotherapy) to high tech surgery.

In the frontlimb, osteoarthritis after elbow dysplasia has a bad prognosis, whereas shoulder problems must be carefully evaluated because the lameness may also have a non-arthrogenic origin. Frontlimb lamenesses are sometimes difficult to diagnose.

Differential diagnosis to these common orthopedic problems are neurologic (disc herniation, peripheric nerve damage) or traumatic (joint fractures, ligament or tendon injuries). There are also a couple of rare diseases, most of them breed specific, which must be kept in mind in orthopedic problems in elderly dogs.

3.2 Coxarthrosis

Coxarthrosis mostly is the result of hip dysplasia. Other pathogenetic mechanisms include Legg Perthes disease, trauma to the acetabulum or femoral head or hip luxation. Dogs are affected from 1 year old. The typical clinical signs are onset lameness, unwillingness to jump into a car or climbing stairs, audible scratching of the toes onto the ground, and short stride. On clinical examination, the most prominent sign is pain during extension and abduction of the hip. The muscle mass is reduced depending on the chronicity of the disease. Coxarthrosis must be differentiated from lumbosacral stenosis or instability by a neurologic examination, on which proprioceptive and sensibility test are performed. Diagnosis is completed with radiographs.

For older dogs, several possibilities for the treatment exist. In every case, the body weight must be observed and held in normal range. Locomotion is restricted to short walks on several occasions during a day rather than one long walk. Non-steroidal inflammatory drugs are given initially and during periods of severe lameness. Chondroprotectives may also be given. Surgical interventions are planned upon the range of motion of the hip joint, the body weight and the observations on the radiograph.

The femoral heck and neck arthroplasty is only indicated in dogs weighing less than 15 kg body weight. The so called PIN-operation is indicated in dogs with moderate coxarthrosis and restricted extension and abduction of the hip joint. The hip joint is approached from the medial side, excising the pectineus muscle. The psoas part of the iliopsoas muscle is then

tenotomized. The joint capsule is freed from nociceptor nerve endings by a periosteal elevator or an electrocautery. The surgery is partly palliative, as it eliminates pain from the joint capsule and from the muscles. Furthermore, the excision of the pectineus muscle reduces the tendency of the femoral head for subluxation. The long term effect of the PIN operations last between 6 months and 5 years.

Figure 3-1: The pectineus muscle is detached

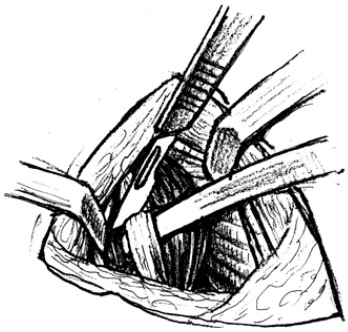

Figure 3-2: the psoas part of the ilipsoas muscle is tenotomized

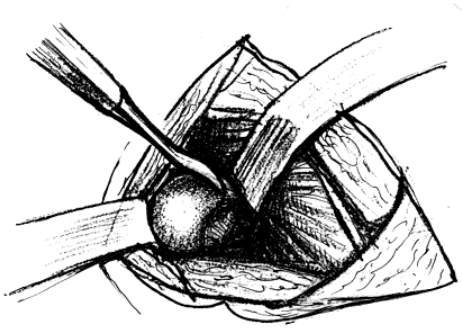

Figure 3-3: Neurectomy of the hip joint capsule

The best method of treatment for coxarthrosis is the total hip prosthesis. Cemented, non cemented and press-fit prosthesis are available. The author is well experienced with the *Zurich Cementless* hip prosthesis. The most important characteristics of the *Zurich Cementless* is avoidance of the coupling effect of the medial and lateral femoral cortices, and stress shielding due to compliance mismatch. The stem is fastened to the medial cortex with screws. This instantly provides a stable fixation, which approximates the normal physiological stress distribution on the proximal femur. It allows bone remodeling around the screws. The initial fixation of the cup is attained by a press fit insertion. The porous design of the cup allows fluid convection and its fixation by osteointegration. The *Zurich cementless* prosthesis can be used in all dogs from 10 months of age and 20 kg bodyweight. Once the bone has fully invaded the cup and filled up the space around the stem, any motion is allowed during the whole life-time of the dog.

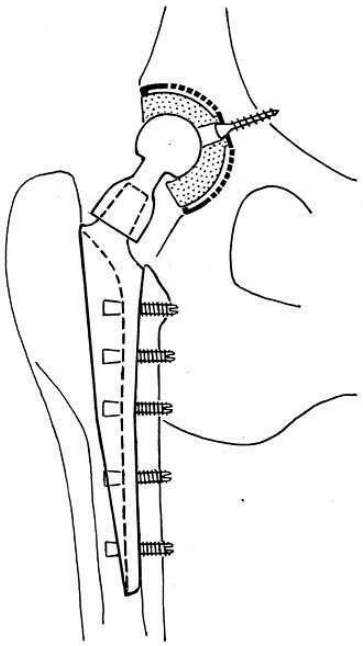

Figure 3-4: Fixation of the *Zurich cementless* hip prosthesis with screws and press fit

Figure 3-5: Postoperative radiograph of a German Shepherd with successful implantation of a hip prosthesis

3.3 Cranial cruciate ligament rupture

Barclay Slocum's approach to stifle biomechanics by introducing muscle forces (1993) has led to a new understanding of the pathogenesis and treatment of cranial cruciate ligament rupture. It must be outlined, that a complete rupture is always preceeded by partial tearing of the cranial cruciate ligament. This is mostly confirmed in the history by intermittent lameness periods, by signs of osteoarthritis, even in so-called acute ruptures, and by macroscopic and microscopic examination of the exised ligaments, which always show degeneration. The force, acting on the ligament, is the cranial tibial thrust. Its magnitude is dependent on body weight and on the geometry of the proximal tibia and the distal femur. Only corrective osteotomies can reduce this force effectively.

A rupture of the cranial cruciate ligament rupture is diagnosed by the drawer sign. The tibia compression test is an alternative for diagnosis. Arthroscopy, MRI or arthrograms are not necessary for diagnosis, but may help detecting meniscal lesions and partial tears. Radiography is made for exclusion of other diseases as OCD, rupture of the long digital extensor, or bone tumor, for perioperative planning and in cases of partial tearing, where the drawer sign is not elicted.

Treatment of cranial cruciate ligament rupture is based onto the body weight. Dogs (and cats) less than 5 kg are treated by NSAID or by posterolateral capsulorrhaphy. Intracapsular

or extracapsular (de Angelis or Flo's procedure, fibula head transposition) techniques are recommend up to 15 kg body weight. It must be recalled, that the prosthesis then undergoes the same forces, which caused rupture of the cranial cruciate ligament. Definitive treatment for large and giant breed dogs is performed either by Slocum's tibia plateau leveling osteotomy (TPLO), the tibia wedge osteotomy (TWO) or by the tibia tuberosity advancement (TTA). All techniques reduce the cranial tibial thrust by either rotating the tibia plateau or by changing the force direction of the quadriceps muscle. The TTA is originated from Zurich university. Nine years experience show a rapid recovery and reliable healing. The intervention is straight forward.

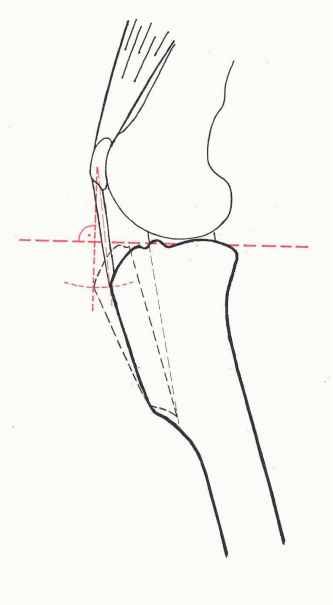

Figure 3-6: Biomechanical explanation for the tibial thrust

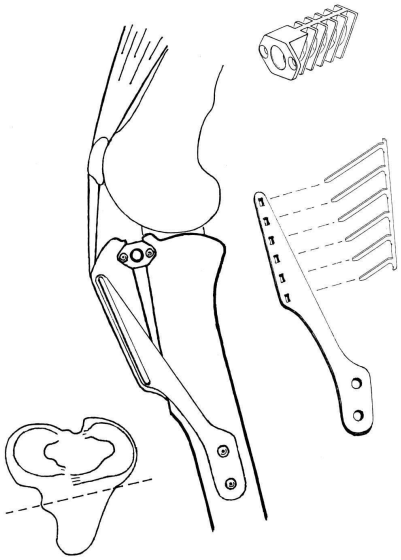

Figure 3-7: Tibial tuberosity advancement (TTA) technique

Figure 3-8: Postoperative radiograph after TTA

All surgical interventions are accompanied by NSAIDs for a rapid recovery. Physical therapy is indicated, where the dogs do not use the their limb after 7 days. Full recovery after TTA is expected after 2-3 months.

3.4 Other orthopedic problems of the hind limb

Well trained dogs may suffer from strains of the iliopsoas muscle. This is diagnosed by extension and inward rotation of the hind limb, during which this muscle is selectively stretched. Digital rectal palpation, and ultrasound may also be diagnostic. Therapy consists first by physical therapy and use of NSAID. Non-responsive strains can be treated by tenotomy of the ilipsoas muscle.

Rottweilers may develop chronic disease of the sesamoid bones in the digital flexors. They are situated on the plantar side to the metatarso-phalangeal joints, and are painful by

hyperextension. Number 2 and 7 are mostly affected. Treatment is either with NSAID and banding or by excision.

German shepherd dogs rarely suffer from contracture and fibrosis of the hamstring muscles (gracilis muscle and others). The typical gait with outward rotation of the hock is diagnostic. No reliable therapy has been proposed up to now.

3.5 Omarthrosis

Medial shoulder luxation is mostly a problem of small dogs. It is diagnosed with abduction of the extended front limbs. More than 20° is pathologic. Transposition of the biceps tendon is a good surgical option to stabilize the joint.

Tenosynovitis of the biceps tendon is often diagnosed. The tendon crosses the shoulder joint, causing pain in the joint and between the two tubercles. First attempts for treatment are with NSAID and restriction of locomotion. Steroid injection into the joint is also effective. Severing of the origin of the biceps tendon and fixation to the proximal humerus with a screw or tunnelling it through the humerus are surgical options with good outcome.

Although a disease of the juvenile dog, OCD lesions are found surprisingly often in senior dogs. They cause moderate osteoarthritis. Treatment is with NSAID or by curettage.

3.6 Elbow arthrosis

Elbow arthrosis ist mostly due to juvenile elbow dysplasia or to elbow trauma. Pain is elicted by extension and rotation of the joint. The elbow is a “non-forgiving” joint. In contrast to the hip joint, where a prosthesis can help, the stifle and shoulder joint, where the disease can be treated quite well, and the carpal and tarsal joints, which can be arthrodesed, the elbow joint allows not much degeneration and can still not be replaced with a prosthesis.

The only treatment is physical therapy, weight loss and the use of NSAID and chondroprotectiva. Elbow arthrodesis is a horrible intervention and does not help much the dog. Limb amputation is a better alternative. A new elbow prosthesis is currently introduced in Europe.

Some other affections of the elbow joint in the senior dog are worth to be described. Traumatic elbow luxation is always lateral, thereby tearing the medial humeroradial collateral ligament. Reposition of the elbow is conducted under anesthesia and with flexed elbow joint. The anconeal processus of the ulna is hooked between the humerus condyles, and the limb is extended, thereby allowing complete reposition of the joint by pressure on the radial head. Unstable joints are operated. The collateral ligaments are sutured. In most instances, the medial collateral ligament tears off the medial epicondyle, leading to screw fixation of the remnants. The limb is fixed in a spica splint for a couple of days.

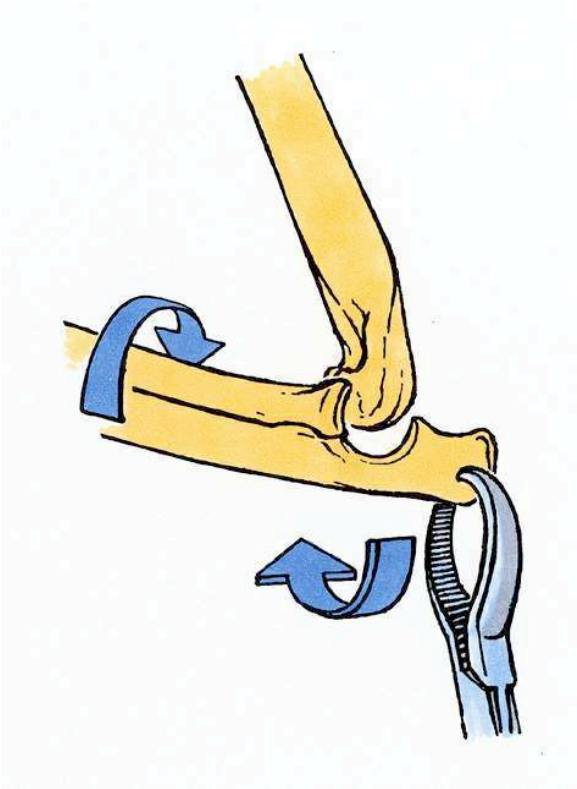

Figure 3-9: First step in reducing laterally luxated elbows – traction and reposition of the anconeal process with elbow in flexion

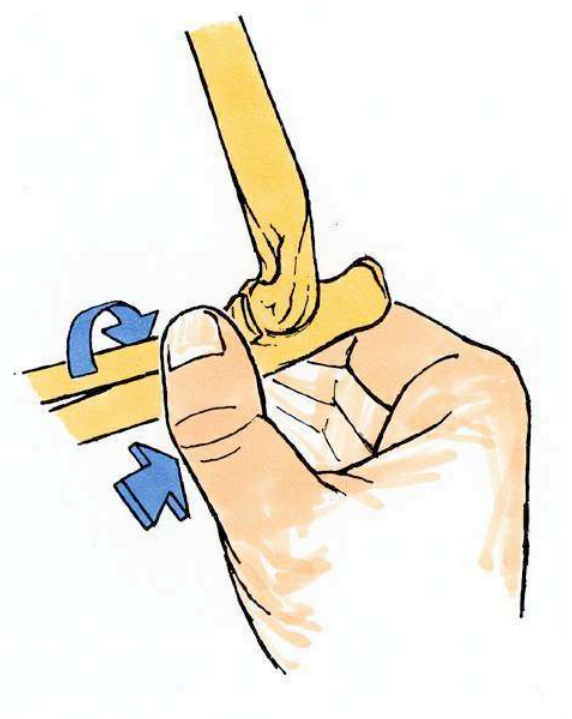

Figure 3-10: Second step in reducing laterally luxated elbows – pressure on the radial head in extended elbow joint

3.7 Other orthopedics problems of the front limb

Epicondylitis of the medial humeral condyle leads to periarticular pain sensation. On the radiograph, ossification of the flexor muscle group close to its origin is visible. The pathogenesis is unclear. Treatment is either with NSAID or by transposition of the flexor group origin to the ulna.

Stenosing synovitis of the abductor pollicis longus muscle was recently detected (Grundmann, 2001). It can be confused with carpal osteoarthritis, although the clinical signs (swelling on the medial aspect of the distal radius, positive Finkelstein test) and the radiographs (firm osseous reaction, no signs of carpal arthrosis) are clear. Treatment is successful in half of the patients with steroid infusion in the tendon sheet. With the other dogs, the tendon is freed surgically from its stenosing bone. Physical therapy and NSAID are given for a longer time.

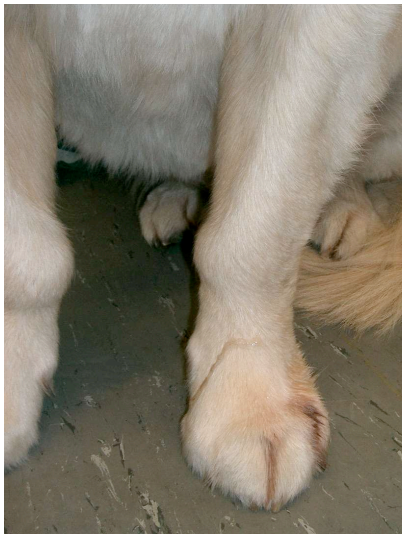

Figure 3-11: Typical swelling on the distal medial radius in a 7 year old Labrador

Figure 3-12: Radiological signs of stenosing tenosynovitis of the abductor pollicis longus muscle

3.8 Neoplasia

Osteosarcoma is the most common neoplasia in the skeleton of the dog and cat. Chondrosarcoma and fibrosarcoma can be seen occasionally, whereas synovial cell carcinoma are rare findings in stifle and tarsal joints.

The sites of predilection for osteosarcoma are the distal radius, proximal humerus, distal femur and proximal tibia. At the time of diagnosis, only amputation with aggressive chemotherapy or radiotherapy may lengthen the life expectancy. Metastasis are often found in the lungs. Diagnosis is confirmed with biopsies.

Figure 3-13: Osteosarcoma on the distal radius in a Rottweiler. See the typical proliferation, periosteal elevation and partial lysis.

Figure 3-14: Osteosarcoma in the proximal humerus of a 10 year old Flat Coated Retriever. The lysis and cortical loss are predominant.