

Comparative investigations on the upper respiratory tract in Norwich terriers, brachycephalic and mesaticephalic dogs

D. A. Koch¹, M. Rosaspina¹, T. Wiestner², S. Arnold³, P. M. Montavon¹

¹Clinic for Small Animal Surgery, ²Equine Clinic and ³Clinic for Small Animal Reproduction, Vetsuisse Faculty, University of Zurich

Summary

For some time Norwich terriers have been known to suffer from respiratory problems. In order to assign this weakness to a pathophysiology, 23 terriers were examined clinically, with laryngoscope and with rhinomanometry. In addition their skulls were dimensioned on radiographs. Widened nostrils, overlong soft palates and the everted laryngeal pouches were consistent with brachycephalic syndrome. Resistance values in the nasal passage corresponded to the appearance in brachycephalic dogs. Skull measurements gave inconsistent results, because length to width ratios and craniofacial angles denoted mesaticephaly, whereas the facial to cranial length ratios (S-index = 0.65) lay in the brachycephalic sector. It can be concluded, that the Norwich terrier breed is in transition towards brachycephaly with some individual dogs already suffering from the brachycephalic syndrome. Breeders are requested to introduce necessary counter measures.

Keywords: Norwich terrier, brachycephaly, respiration, dyspnea, skull

Vergleichende Untersuchungen am oberen Respirationstrakt bei Norwich Terriern, brachycephalen und mesocephalen Hunden

Schon seit längerer Zeit ist bekannt, dass Norwich Terrier vermehrt an Atemwegsproblemen leiden. Um die Erkrankungen einer Pathophysiologie zuordnen zu können, wurden 23 Norwich Terrier klinisch, laryngoskopisch, rhinomanometrisch und ihre Schädel radiologisch untersucht. Weite Nüstern, zu lange Gaumensegel und evertierte Larynxtaschen sowie die erhöhten Werte der Widerstandsmessungen in der Nasenpassage entsprachen dem Bild des brachycephalen Syndromes. Die Schädelvermessungen zeigten ein uneinheitliches Bild. Der Längen-Breiten-Index und der kraniofaziale Winkel entsprechen den Werten von mesocephalen Hunden, während der Gesichtsschädel-Gehirnschädellängen-Index (S-Index von 0.65) deutlich im Bereich für Brachycephalie lag. Daraus kann gefolgert werden, dass die Rasse Norwich Terrier sich auf dem Weg zu den brachycephalen Rassen befindet und verschiedene Einzeltiere bereits am brachycephalen Syndrom leiden. Die Züchter sind aufgerufen, entsprechende Gegenmassnahmen zu ergreifen.

Schlüsselwörter: Norwich Terrier, Brachycephalie, Atemwege, Dyspnö, Schädel

Introduction

Norwich terriers and Norfolk terriers are small dogs of between 5 to 8 kg body weight (BW), of common ancestry. In 1906, the lines were separated into tilted eared dogs (Norwich terriers) and hanging eared dogs (Norfolk terrier) and finally recognized by the United Kingdom Kennel Club in 1964. The Norwich terrier breed standard has been described as having a wide skull with a facial skull one third shorter than the cephalic skull. Although

not known to be categorized as a brachycephalic breed, this shortening of the relative length of the nose may be the reason why it is anecdotally described (Suggs, 1995; Maza, 2003; Slater, 2004), that Norwich terriers suffer from respiratory problems, which are normally summarized under the term brachycephalic syndrome. The goal of this study was to clinically investigate within a population of Norwich terrier, if they showed signs of the brachycephalic syndrome and if their skull dimensions allowed them to be classified as a brachycephalic breed.

2 Originalarbeiten/Original contributions

Material and Methods

Animals

The study population consisted of 3 groups: Norwich terriers (NW), non-brachycephalic dogs (Non-BC), and brachycephalic dogs (BC). The NW group was composed of 23 dogs between 1 and 13 years of age, 13 males and 10 females with a body weight (BW) of 5.0 to 8.5 kg, which were supplied by the Swiss Norwich terrier club. The Non-BC group was partly selected from another investigation regarding repeatability of rhinomanometry (8 female Beagle dogs, weighing 8.2 to 10.3 kg). For a part of the study where nostrils were measured, another 22 non-brachycephalic dogs were added to the group. They were presented for surgery unrelated to the respiratory system issues (mainly neutering). The BC-group was composed of 8 client-owned dogs, which had been referred to the Vetsuisse Faculty, University of Zurich for surgical correction of the brachycephalic syndrome. The owners agreed to the planned investigations, which were all done prior to the selected surgery for which they had visited the Vetsuisse Faculty.

Clinical examination and anesthesia

All dogs were clinically examined. Blood samples for haematological and biochemical analysis were taken and considered normal in all cases. Dogs were sedated with buprenorphin (0.007 mg/kg, IM, Temgesic®, Essex Chemie AG, Luzern, Switzerland) and acepromazin (0.03 mg/kg, IM, Prequillan®, FATRO s.p.a., Ozzano Emilia, Italy) mixed in one syringe. Subsequently, anaesthesia was induced with a first bolus of propofol (4 mg/kg IV, Propofol-®Lipuro 1%, Braun Medical AG, Emmenbrücke, Switzerland), just enough to assess the pharyngeal area. After intubation, anaesthesia was maintained with nitrous oxide and oxygen (3:2) as well as Isoflurane (Attane®, Provect AG, Lyssach, Switzerland) at 2–3%.

Respiratory tract measurement

The following clinical parameters were recorded with the patient not intubated. The length of the soft palate was visually assessed by means of an endoscope with the tongue in resting position. The excess length of the palate was expressed as the part overlapping the tip of the epiglottis divided by the epiglottis length from the tip to the base. The degree of tracheal collapse was noted (grade 1 to 4, according to Tangner and Hobson, 1982). The other parameters assessed in the oropharynx were the tonsils (normal/enlarged), the laryngeal pouches (everted/not everted), and the rima glottidis (collapsed/not collapsed). A photograph of the planum nasale together with a ruler was taken. The nostril ratio was expressed as the largest horizontal width divided by half of the largest width of

the planum nasale. These visually assessed data were only recorded in the NW and non-NW group.

The nasal resistance R_N of the dogs was determined by passive rhinomanometry, a method commonly used to calculate R_N from simultaneous measurement of nasal air flow (Q_N) and resulting trans-nasal pressure difference (P_N) (Pallanch et al., 1993). The passive rhinomanometry method, adapted to dogs by Wiestner et al. (2007), relies on measurements using an artificial ventilation of the nose, mimicking inspiration and expiration. Q_N and P_N were recorded with a multipurpose flow recording unit (Exhalizer-D® with Spiroware® Software, Eco Medics AG, Duernten, Switzerland). $P_{N\text{ met}}$ and $R_{N\text{ met}}$ were calculated individually for a so called “metabolic” air flow rate $Q_{N\text{ met}}$, which was proportional to the respective body size as $Q_{N\text{ met}} = 0.018 \text{ BW}^{0.75} \text{ l/s}$.

Skull parameters

Radiographs of the skull in dorsoventral directions were taken with the dog's hard palate parallel to the table, estimated visually by the corresponding position of the teeth of the upper jaw. The radiographs were accepted, when the left and right side of the skull were considered congruent. Radiographs of the skull in laterolateral directions were taken with the mouth open, the sagittal line of the skull parallel, and the palate positioned perpendicular to the table. They were accepted, when the temporomandibular joints were projected over each other. The following parameters were retrieved from the radiographs:

- the skull index (S-index) (Balli, 2004; Koch et al., 2012) was calculated by dividing the length of the facial skull (from the rostral border of the cavum cranii to the rostral border of the os incisivum) by the length of the brain case (from the caudal outline of the os occipitale, beginning at the dorsal border of the foramen magnum, to the rostral border of the cavum cranii). The index was retrieved from radiographs in dorsoventral direction. Brachycephalic dogs are considered to have an S-index < 1.25 .
- length of the skull/width of the skull (LW-index). This index was the radiographic equivalent of the index used by Evans (1993), which used prepared skulls. The length of the skull was measured as the distance between the rostral border of the os incisivum to the caudal edge of os occipitale, at the dorsal border of the foramen magnum. The width of the skull was the greatest distance between the outer borders of the two zygomatic arches. Both distances were retrieved from radiographs in a dorsoventral direction. Brachycephalic dogs are considered to have a LW-index < 1.44 .
- the CFA (craniofacial angle) according to Regodon et al. (1993) is defined as the angle between a first line, which connects the sulcus chiasmatis (caudal border of the optic canal on the floor of the os presphenoidale) with the caudoventral border of the os occipitale and a second line, which is the prolongation of the palatum

durum. The CFA was determined with laterolateral radiographs. CFA are considered to be between 9 and 14° for brachycephalic, between 19 and 21° for mesati-cephalic dogs, and between 25 and 26° for dolichocephalic dogs.

Statistical analysis

Differences between the continuous variables of the 3 dog groups were assessed with one way analysis of variance and succeeding post-hoc multiple comparison tests (Bonferroni Posthoc test). Ordinary data from clinical and laryngoscopic examinations were compared between the Norwich terriers and non-brachycephalic dogs with Fisher's exact tests. All statistics were done with Stat View 5® (Abacus Software, Letchworth, UK) and $p < 0.05$ was considered as significant.

Results

The clinical data from the NW and the Non-BC group were compared (Tab. 1). Resting capillary refill time, heart rate, respiratory rate and colour of the mucous membranes were within normal limits. Cardiac and pulmonary auscultation were normal. Six out of 23 NW had anamnistically shown stridor or stertor, whereas no dogs from the non-BC was reported to have pathological sounds from the upper airways. Palpation on the trachea elicited coughing in 7 Norwich Terriers and in none of the dogs from the Non-BC group. Laryngoscopy revealed pathological findings in all 23 Norwich terriers, whereas none of the non-BC had abnormalities. These differences were significant. No laryngoscopy was made on the BC group.

The nostril ratio (Fig. 1) was significantly smaller in the NW group (0.26 ± 0.03) compared to the non-BC group (0.34 ± 0.04) and the expanded second group of 22 non-brachycephalic dogs (0.36 ± 0.08). The rhinomanometric measurements (Fig. 2) showed that the transnasal resistance ($R_{N\text{met}}$) was significantly higher in the NW group

($7.3 \pm 2.8 \text{ kPa (l/s)}^{-1}$) compared to the Non-BC group ($1.8 \pm 0.7 \text{ kPa (l/s)}^{-1}$), but not different to the BC group ($6.0 \pm 2.6 \text{ kPa (l/s)}^{-1}$).

The NW group had S-index values (0.65 ± 0.36), which were not different than those of the BC group (0.63 ± 0.11). The S-index from the Non-BC group (1.37 ± 0.18) was significantly higher than in the other

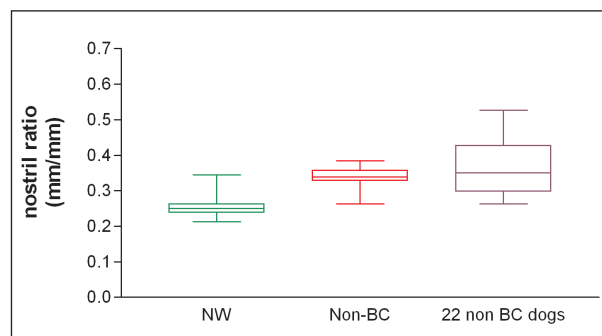


Figure 1: The nostril ratio of 23 Norwich terriers (NW), 8 non-brachycephalic dogs (Non-BC, Beagles) and another 22 non-brachycephalic dogs of other breeds, visualized as boxplots (median, 25 and 75 % percentiles, minimal and maximal values).

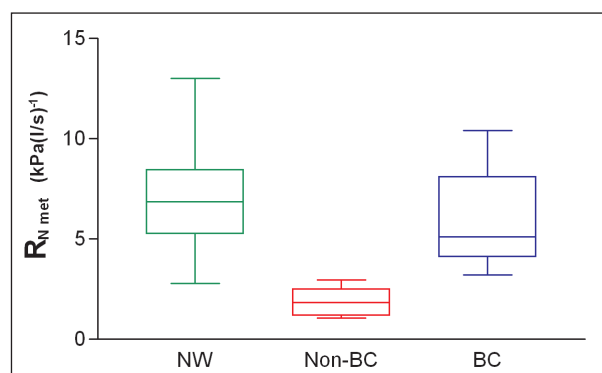


Figure 2: Transnasal resistance ($R_{N\text{met}}$) values of 23 Norwich terriers (NW), 8 non-brachycephalic dogs (Non-BC) and 8 brachycephalic dogs, visualized as boxplots (median, 25 and 75 % percentiles, minimal and maximal value).

Table 1: History and laryngoscopic findings of 23 Norwich terriers and 14 non-brachycephalic dogs. Numbers delineate occurrence of corresponding finding.

	Norwich terrier group (23 dogs)	Non brachycephalic group (8 dogs)
History		
Breathing sounds	6	0
Coughing	7	0
Laryngoscopy		
Elongated soft palate	19	0
Enlarged tonsils	20	0
Everted laryngeal pouches	17	0
Collapsing laryngeal entrance	6	0
Narrow rima glottidis	6	0

4 Originalarbeiten/Original contributions

two groups (Fig. 3). The LW-index (Fig. 4) showed that 22 out of 23 Norwich terriers were classified as mesaticephalic and 1 Norwich terrier was dolichocephalic according to Evans (1993). All non-BC dogs (Beagles) were categorised mesaticephalic. Six out of 8 brachycephalic dogs could be assigned to the brachycephalic group and 2 were mesaticephalic. The values from the NW group (1.60 ± 0.14) were not different to the non-BC group (1.68 ± 0.07), but significantly higher than those from the BC-group (1.14 ± 0.21).

Classifying the dogs with the CFA according to Regodon et al. (1993) revealed that 9 Norwich terriers were in the range defined as mesaticephalic, while the other 14 dogs could not be assigned to a group because their value was between the higher limit for brachycephalic (14°) and the lower limit for mesaticephalic dogs (19°). The non-BC group included 2 dolichocephalic dogs and 1 mesaticephalic dogs, while the others were between the corresponding ranges. In the BC group, 4 dogs were brachycephalic, 1 was a mesaticephalic and 3 were between the corresponding ranges. The CFA of the NW group (21.5 ± 2.2) were not different than those of the

non-BC group (23.6 ± 1.8), but significantly higher than those from the BC group (15.8 ± 4.2) (Fig. 5).

Discussion

Upper respiratory tract problems, epilepsy and allergies in Norwich terriers are well known within the breeding community. Suggs (1995) reports 32 respiratory problems in 346 dogs. A survey by Slater (2004) with 1075 Norwich terriers reveals 128 dogs with respiratory problems, of which 66 have excessive palatal length. From a questionnaire by Maza (2003) on 227 Norwich terriers, we know that 96 of the dogs snored at sleep and 17 dogs have respiratory problems. More detailed information on the upper airways is gained from Ruchti (2009), who compared 125 Norwich and 11 Norfolk terriers using laryngoscopy, radiography and blood panels. The prevailing finding was the overlong soft palate, followed by everted laryngeal pouches, edemas in the pharynx and the altered position of the laryngeal cartilages. A scoring system allowed for their classification into different degrees. According to the author, 80 % of the Norwich terriers had moderate to severe respiratory problems, whereas no Norfolk terrier showed similar signs. Because no narrow nostrils were observed and the radiographs showed no obvious signs of brachycephalic head shape, the respiratory problems in the Norwich terriers were not defined as brachycephalic syndrome and the breed not classified as brachycephalic.

The results of our study are supplementary to the above mentioned reports on Norwich terriers. More detailed information was taken from the radiographs, and a novel technique for assessing nasal airway resistance (Wiestner et al., 2007) was used. Most of the results were compared to brachycephalic and normocephalic dogs.

The following parameters obtained from Norwich terriers showed similarities with a brachycephalic breed and with the brachycephalic syndrome:

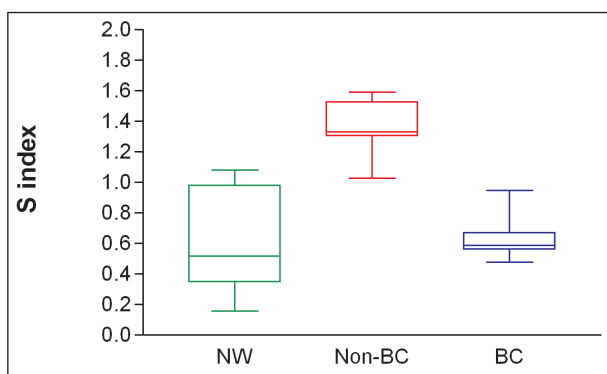


Figure 3: S-index values of 23 Norwich terriers (NW), 8 non-brachycephalic dogs (Non-BC) and 8 brachycephalic dogs, visualized as boxplots (median, 25 and 75 % percentiles, minimal and maximal values).

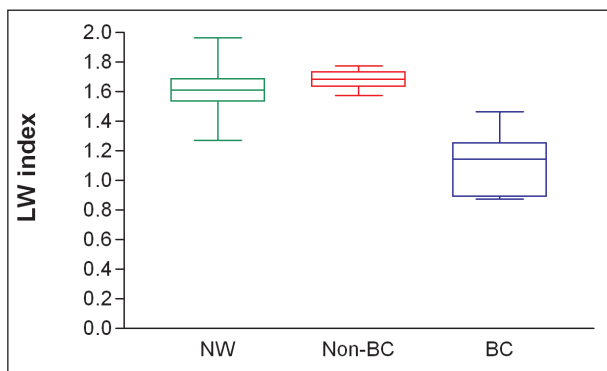


Figure 4: LW-index of 23 Norwich terriers (NW), 8 non-brachycephalic dogs (Non-BC) and 8 brachycephalic dogs, visualized as boxplots (median, 25 and 75 % percentiles, minimal and maximal values).

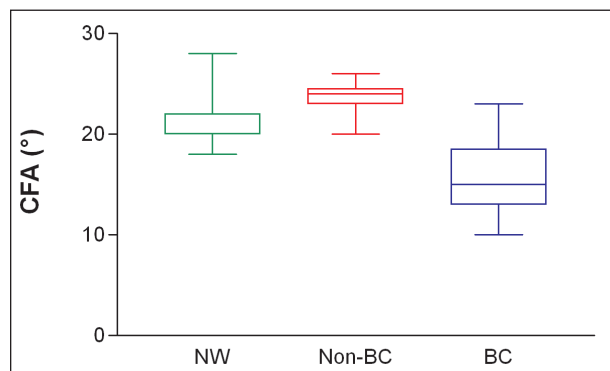


Figure 5: Craniofacial angles of 23 Norwich terriers (NW), 8 non-brachycephalic dogs (Non-BC) and 8 brachycephalic dogs, visualized as boxplots (median, 25 and 75 % percentiles, minimal and maximal values).

The nostril ratio was smaller in the NW than in the extended non-BC group. It can be assumed that the Norwich terriers would have a similar problem as the brachycephalic dogs, from which is known, that narrowed nostrils contribute to laboured breathing (Harvey, 1982). The results of the laryngoscopic examination, mainly the lengthened soft palate, matched the observations made in brachycephalic dogs (Harvey, 1982), whereas no control dogs of the Non BC group showed such elongation. These findings in Norwich terriers are confirmed by recent research (Ruchti, 2009). The eversion of the tonsils, the everted laryngeal pouches and a narrow rima glottidis are common observations in dogs with a brachycephalic syndrome and are explained by an increased negative pressure in the pharynx (Ohnishi et al., 1971; Wiestner et al., 2007). As the tonsils are not exposed to the main airstream, tonsillectomy is not recommended in the treatment of the syndrome, whereas removal of the laryngeal pouches is beneficial (Harvey, 1982).

The rhinomanometric measurements, expressed by the transnasal resistance (R_{Nmet}) were similar in NW and BC dogs and higher than the Non BC dogs. According to previous investigations (Ohnishi et al., 1971; Balli, 2004; Wiestner et al., 2007), this increased resistance in the space between the nasal plane and the soft palate is a reliable parameter and pathophysiological finding in dogs with a brachycephalic skull shape. It is speculated, that this increased resistance is generated at the nasal entrance and is responsible for all the other symptoms and findings in the brachycephalic syndrome, which are secondary to laboured inspiration and increased negative pressure in the upper airways. These secondary findings include the elongated and thickened soft palate, the protrusion of soft tissues in the nasopharynx, the eversion of the tonsils and the laryngeal pouches, the collapsing larynx, and even the gliding hiatal hernia with temporary displacement of the stomach into the thorax.

The following parameters obtained from the radiographs led to some contradictory conclusions: The S-index of 0.65 is far below the boundary value of 1.25 set between BC and Non-BC dogs (Balli, 2004). This means, that the facial skull has insufficient length, when compared to the cranial skull length. However, the measurements on the

CFA and the LW-index would imply that the Norwich terrier is not a brachycephalic dog. Ruchti (2009), who studied the skull shapes by comparison to the wolf, also reported that Norwich terriers would not be brachycephalic, but did not use statistical methods. The confusion on the different indices cannot be solved definitely. However, the fact that one out of three indices points towards brachycephaly, must be taken into consideration. The statement from Ruchti (2009), that the skull shape of the Norwich terrier is not brachycephalic, is challenged herewith.

The Norwich terrier is a breed, whose skull shape has shows characteristics of brachycephaly. Although the length to width ratio and the craniofacial angle are similar to Beagle dogs, the relative length of the facial skull to the cranial skull seems to shorten in a way which is also known in brachycephalic dogs. This should alert the breeders, because the Norwich terrier is now on a slow transition towards the shortening of the nose. As in all other breeds, this transition takes places in a broad spectrum of varieties, in which some individuals still have mesaticephalic skull shapes and others are already brachycephalic. This may explain why Norwich terriers do not all suffer from respiratory problems, and why not all studies have come to the same conclusion regarding the denotation of this disease. Our investigation has found the typical clinical manifestations of the brachycephalic syndrome, which is supported by previous surveys (Suggs, 1995; Maza, 2003; Slater, 2004) and partly by the study from Ruchti (2009). However, she did not find any widened nostrils, but only the lengthened soft palates and protruding soft tissue in the upper airways, and she therefore assigned the disease to another pathophysiology.

Conclusions

A part of the population of the Norwich terriers is suffering from brachycephalic syndrome. Breeders should be encouraged to select dogs for breeding that have normal findings during laryngoscopy including normal lengths of the soft palate and an S-index considerably higher than the present value of 0.65.

Examens comparatifs du système respiratoire supérieur de Norwich Terriers, chiens brachycéphales et mésocéphales

On sait depuis longtemps déjà que le Norwich Terrier souffre de plus en plus de problèmes respiratoires. Afin de pouvoir donner une explication pathophysiologique à ces problèmes, on a examiné 23 Norwich Terriers sur le plan clinique, laryngoscopique, rhinomanométrique ainsi qu'avec des radiographies du crâne.

Studi comparativi del tratto respiratorio superiore nei Terrier Norwich e nei cani brachicefali e mesocefali

Da molto tempo è noto che i Terrier Norwich soffrono di vari problemi respiratori. Sono stati esaminati 23 Terrier Norwich, sotto l'aspetto clinico, laringoscopico, rinomanometrico ed è stata effettuata una radiografia del cranio, al fine di classificare le malattie della fisiopatologia. Narici ampie, eccessiva lunghezza del pala-

6 Originalarbeiten/Original contributions

Des narines larges, un voile du palais trop long et des ventricules laryngés éversés, de même que des mesures de résistance augmentées dans les conduits nasaux correspondaient à l'image du syndrome brachycéphale. Les mesures du crâne présentaient un tableau non uniforme. L'index longueur-largeur et l'angle cranio-facial correspondaient à ceux de chiens mésocéphales, alors que l'index splanchnocrâne-neurocrâne (Index S de 0.65) était clairement dans la zone du brachicéphalisme. On peut en déduire que le Norwich Terrier se trouve sur le chemin du brachicéphalisme et que certains chiens souffrent déjà d'un syndrome brachycéphale. Les éleveurs doivent donc prendre des mesures pour lutter contre cette évolution.

to molle, eversione dei sacculi laringei e dei valori più elevati delle misure di resistività al passaggio dell'aria nel naso danno una chiara immagine della sindrome brachicefala. Le misurazioni del cranio mostrano un quadro eterogeneo. L'indice lunghezza-larghezza e l'angolo cranio-facciale corrispondono ai valori dei cani mesocefali mentre l'indice cranio-facciale e le lunghezze cranio cerebrali (indice S di 0.65) si trovano chiaramente nell'intervallo di una brachicefalia. Si può quindi concludere che la razza Terrier Norwich va già in direzione delle razze brachicefale e singoli animali soffrono già di vari disturbi associati alla sindrome brachicefala. Gli allevatori sono invitati a prendere le contromisure adeguate.

References

- Balli A.*: Radiologische Methode zur Klassifizierung der Schädeltypen und Beurteilung des Brachycephaliegrades beim Hund. Dissertation, Universität Zürich, 2004.
- Evans H. E.*: The Skeleton. In: Millers' anatomy of the dog. Hrsg. H. E. Evans, W. B. Saunders Company, Philadelphia, 1993, 122–218.
- Harvey C. E.*: Upper airway obstruction surgery 1: Stenotic nares surgery in brachycephalic dogs. *J. Am. Anim. Hosp. Assoc.* 1982, 18: 535–537.
- Harvey C. E.*: Upper airway obstruction surgery 2: Soft palate resection in brachycephalic dogs. *J. Am. Anim. Hosp. Assoc.* 1982, 18: 538–544.
- Harvey C. E.*: Upper airway obstruction surgery 3: Everted laryngeal saccule surgery in brachycephalic dogs. *J. Am. Anim. Hosp. Assoc.* 1982, 18: 545–547.
- Koch D. A., Wiestner T., Balli A., Montavon P., Michel E., Scharf G., Arnold S.*: Proposal for a new radiological index to determine skull conformation in the dog. *Schweiz. Arch. Tierheilk.* 2012, 154: 217–220.
- Maza B.*: Atemwegsbelastungen beim Norwich Terrier; Erhebungsbogenaktion. 2003.
- Ohnishi T., Ogura J. H., Nelson J. R.*: Effects of nasal obstruction upon the mechanics of the lung in the dog. *Laryngoscope* 1971, 81: 220–225.
- Pallanch J. F., McCaffrey T. V., Kern E. B.*: Evaluation of nasal breathing function. In: *Otolaryngology – head and neck surgery*. Hrsg. C. W. Cummings, Mosby – Year Book, Inc, St. Louis, Missouri, 1993, 665–686.
- Regodon S., Vivo J. M., Franco A., Guillen M. T., Robina A.*: Craniofacial angle in dolicho-, meso- and brachycephalic dogs: radiological determination and application. *Anat. Anz.* 1993, 175: 361–363.
- Ruchti M.*: Das Obere Luftweg-Syndrom beim Norwich Terrier – Beschreibung der Erkrankung und der Untersuchungsmethoden, sowie Entwicklung und Evaluierung eines zuchthygienisch nutzbaren Scoring-Schemas. Dissertation, Universität Bern, 2009.
- Slater M.*: Report for the Norwich Terrier health survey. 2004.
- Suggs C.*: NNTC Health survey. *Norwich und Norfolk news* 1995, 70: 26–29.
- Tangner C., Hobson H. P.*: A retrospective study of 20 surgically managed cases of collapsed trachea. *Vet. Surg.* 1982, 11: 146–149.
- Wiestner T. S., Koch D. A., Nad N., Balli A., Roos M., Weilenmann R., Michel E., Arnold S.*: Evaluation of the repeatability of rhinomanometry and its use in assessing transnasal resistance and pressure in dogs. *Am. J. Vet. Res.* 2007, 68: 178–184.

Corresponding author

Daniel Koch, DVM, Diplomate ECVS
Daniel Koch Kleintierchirurgie AG
Ziegeleistrasse 5
8253 Diessenhofen
Switzerland
Tel.: +41 (0)52 657 30 00
daniel.koch@dkoch.ch

Received: 8 April 2013

Accepted: 30 August 2013